



CASE REPORT

Surgical Management of Stillman's Cleft Using Free Gingival Graft

Jawaher Abdulla Al Mudahki^{1,*}, Kanak Ketan Ganguly²

¹Resident, DDS, MFD RCS (Ireland), Department of Dental and Maxillofacial center, Royal Medical Services, Bahrain Defense Force Hospital, Kingdom of Bahrain

²Chief Resident, BDS, MDS, MFD RCS (Ireland) Department of Dental and Maxillofacial center, Royal Medical Services, Bahrain Defense Force Hospital, Kingdom of Bahrain

***Corresponding author:**

Dr. Jawaher Abdulla Al Mudahki, Resident, DDS, MFD RCS (Ireland), Department of Dental and Maxillofacial center, Royal Medical Services, Bahrain Defense Force Hospital, Kingdom of Bahrain; Email: jawaher-almudahki@hotmail.com

Received date: April 13, 2020; **Accepted date:** June 8, 2020; **Published date:** June 30, 2020

Abstract

Stillman's cleft is a mucogingival triangular shaped defect, commonly observed on the buccal or labial surface of the gingiva. The etiology behind this lesion is believed to be multifactorial and unclear. The prognosis of Stillman's cleft varies depending on the extent of the cleft; some lesions may repair spontaneously while others require precise examination and evaluation to provide the proper management. This paper reports a case of a patient with Stillman's cleft that was treated by free gingival grafting.

Keywords: Gingiva; Gingival recession; Gingivitis; Inflammation; Periodontitis.

Introduction

Stillman's cleft is defined as a mucogingival triangular shaped defect mainly seen on the buccal or labial surface of the gingiva. This defect can be noticed as a depression or a distinctly demarcated fissure; it may also be associated with ulceration. The cleft extends from the cervical margin of gingiva and up to 5-6mm of length depending on the severity of the lesion.¹ As the lesion progresses, the plaque control is compromised and therefore may result in the inflammation of the associated oral mucosa.²

Paul Roscoe Stillman was the first to describe this pattern of gingival cleft which is related to occlusal trauma, it may also be associated with marginal gingivitis or mild periodontitis.³ Stillman's cleft is

classified into 'simple' which are single direction clefts or 'composed' which are multi-directional clefts.¹

The etiology and pathogenesis of Stillman's cleft remains unclear; but occlusal trauma due to interferences is accepted. A study in 2013 by Prasad et al; have inspected teeth that were associated with Stillman's cleft and upon examination all the examined teeth related to this lesion turned out to have occlusal wear.⁴ A further assessment included the evaluation of the presence of occlusal interferences during laterotrusion, mediotrusion and protrusion. Teeth which were involved in occlusal interferences also had gingival clefts, which shows a strong correlation among gingival clefts and occlusal trauma.⁵ Other possible causative

factors are periodontal inflammation, traumatic tooth brushing, improper use of dental floss and interdental brushes.^{6,7}

Stillman's clefts are commonly reported to be asymptomatic and are consequently diagnosed at a later stage. On the other hand, in cases like the case discussed here, a patient may feel severe discomfort or pain especially when the lesion is associated with inflammation.⁸ Prognosis of these clefts is variable depending on the extent of the defects.⁹ Lesions that are confined within the connective tissue may be considered reversible and the removal of the causative factor is sufficient to allow the lesion to heal uneventfully, but if the cleft involves the full thickness of the connective tissue as in this case, then the lesion is irreversible and may require surgical intervention.

Case presentation

A forty-three-year-old female patient presented to our clinic complaining of receding gums and pain in upper left canine since the past two months. The patient was a known case of Hypothyroidism and Gastro-esophageal reflux disease, for which she was under medications. She was a non-smoker and denied the history of any known parafunctional habits.

On clinical examination, the labial gingiva of the upper left canine displayed a triangular shaped defect that was associated with an inflamed, enlarged, edematous and ulcerated marginal gingiva. Further minute observation of the marginal gingiva showed the presence of a fine apostrophe shaped cut or cleft, a sign that has historically been known as 'Stillman's Cleft' (Figures 1 & 2). The occlusal surfaces of the

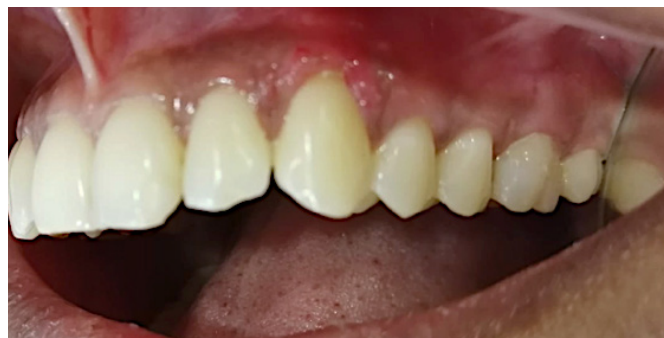

Figure 1: Upper left canine shows a "V" shaped gingival recession that is associated with ulceration, inflammation, and enlargement of the marginal gingiva.

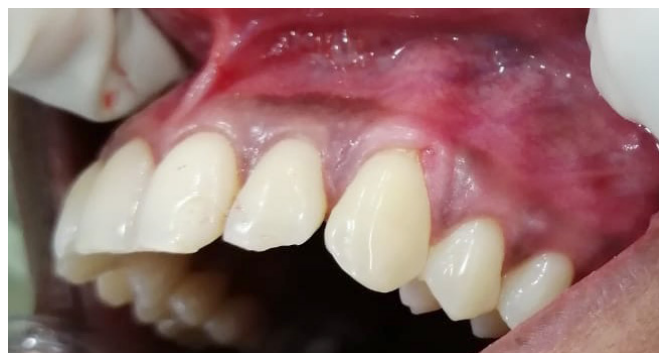

Figure 2: Pre-operative photograph of a typical presentation of Stillman's cleft, which shows clear resolution of the previously related inflammation.

premolars and molars showed generalized erosion and prominent wear facets related to attrition, which indicated the presence of a parafunctional habit such as bruxism or clenching that was not reported by the patient.

Periodontal examination revealed minimal bleeding on probing in relation to the upper left canine, probing depth did not exceed 4mm. Gingival recession was categorized as Class I-A (Cairo classification, 2011) in the upper anteriors, premolars and molars; the teeth were also associated with mild abfraction lesions.¹⁰ The lower centrals and laterals were grouped as Class II gingival recession (Cairo classification, 2011).¹⁰ Full mouth periodontal probing revealed shallow pockets of up to 4 mm in the upper and lower molar regions bilaterally, with slight bleeding on probing. The patient otherwise maintained fair oral hygiene no plaque was evident, only scanty calculus flecks were detected.

The clinical features were suggestive of a provisional diagnosis of Periodontitis, Stage I Grade A (2017 Classification of Periodontitis by European federation of periodontology (EFP) and American Academy of Periodontology (AAP)). To arrive at the final diagnosis the results of blood investigation and a Panoramic radiograph were reviewed. The patient had a normal complete blood count (CBC) and glycosylated hemoglobin (HbA1C) and tested negative for Human Immunodeficiency virus (HIV), Hepatitis B virus (HBV), Hepatitis C virus (HCV) and Syphilis during the routine serology test. The radiograph revealed less than 15% alveolar bone loss at the site of maximum damage that could be attributed to localized periodontitis in the upper right and left 2nd molars distally.

The differential diagnosis considered for this case were as follows: a) Traumatic ulcer, b) Acute necrotizing ulcerative gingivostomatitis (ANUG) and c) gingival abscess. As the patient gave no history of trauma the patient was educated regarding the benefits of using a soft-bristled toothbrush and Stillman's technique of brushing was demonstrated. However, the lesion persisted during the second recall. Hence the diagnosis of traumatic injury was ruled out. As the lesion did not have any typical manifestations such as necrosis, viz, sloughing of pseudomembrane and high intensity pain, ANUG was ruled out. The preliminary exploration of the lesion did not reveal the presence of any foreign object, nor was any suppuration found. Mild enlargement of the marginal gingiva was diffuse and not fluctuant; hence the possibility of gingival abscess was ruled out.¹¹ Considering these facts, a Provisional diagnosis of Periodontitis Stage I grade A with the presence of Stillman's cleft was accepted as the final diagnosis.

The treatment planning was outlined. Full mouth scaling was performed, abfraction lesions were restored using composite resin restorative material, and a night guard was fabricated and given to the patient to support in refraining from the parafunctional habit and prevent further loss of the tooth structure.

The patient came back after two months with the same complaint, i.e. severe sensitivity and pain in upper left side pointing to the upper left canine. The labial gingival margin showed a persistent Stillman's cleft with mild inflammation. Since improvement of oral hygiene and removal of occlusal interferences and use of atraumatic brushing technique did not regress the lesion, a decision was made to treat the Stillman's cleft with a free gingival graft. An informed written consent was taken, and pre-operative images were captured.

At this stage, a dilemma presented itself regarding the choice of donor site for the free gingival graft as the lesion was in a zone of high aesthetic concern. Tissue grafted from the palate would have a lighter color than the labial gingiva of the patient which was highly pigmented. After a survey of the gingiva in various regions of the patient's mouth regarding

the tissue thickness, available width for harvesting and nearest color match to the recipient site, the attached gingiva buccal to upper left second molar was selected as the donor site.

Excision of the lesion under local anesthesia was performed. The exposed root surface was debrided by ultrasonic scaler. A free gingival graft was harvested from the attached gingiva buccal to the upper left second molar. Post-operatively the patient was prescribed Ibuprofen 400mg, to be taken every 8 hours for 3 days and Chlorohexidine 0.12%, 15ml twice daily, half an hour after tooth brushing (Figure 3).

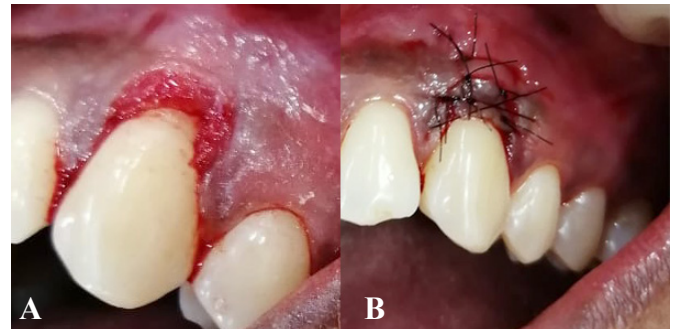


Figure 3: [A] Lesion is excised. [B] The root is covered with free gingival graft harvested from the attached buccal gingiva.

The patient was recalled after 10 days for follow up; post-operative healing was uneventful; the patient reported very mild discomfort in the donor site only for the first two days after surgery. The recession was completely covered with no residual soft tissue defect. The donor site also showed complete healing. The color of the grafted tissue was indistinguishable from the neighboring recipient gingiva.

The patient was recalled again after 6 months for further follow-up to assess the procedure outcomes (Figure 4). The gingival tissue texture, color and

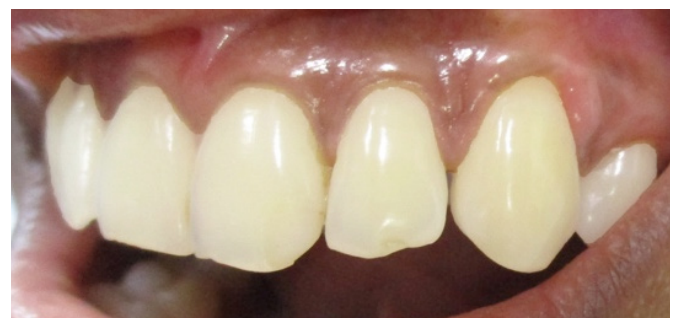

Figure 4: Post-operative image after six months, shows complete healing of gingiva with no signs of inflammation.

position were stable, with a probing depth of 1 mm; the results were hence considered excellent in terms of root coverage and aesthetics.

Discussion

To date, there are no sufficient published studies on the etiology and pathogenesis of Stillman's cleft. Most of the publications concerning Stillman's cleft suggest that the cause is multifactorial while others declare it unknown. This might be because most lesions are asymptomatic or that the lesion is uncommonly reported in literature.¹²

In the discussed case, the cause of the lesion is multifactorial; the first factor is the compromised periodontal health of patient which displayed generalized recession and marginal gingivitis, the second factor is the occlusal wear 'attrition' and 'abfraction' lesions that strongly suggests the presence of occlusal trauma. An external traumatic factor in the etiology cannot be excluded due to presence of ulceration of the lesion which might be a result of gingival tissue trauma.¹³

The initial step of treatment was conservative including creating awareness of bruxism habit, scaling, oral hygiene instructions and night guard. Unfortunately, the conservative approach seemed to be insufficient to promote healing of the lesion. The patient was still complaining of pain; hence a surgical approach was considered, the lesion was excised and a free gingival graft from the attached buccal mucosa was utilized to cover the exposed root surface.

Free gingival graft was proven to be the most predictable procedure to achieve complete root coverage.¹³ A systematic review by Roccuzzo M et al, also confirmed that in Class I gingival tissue recession 70%-85% root coverage can be anticipated.¹⁴

Conclusion

The case described above has demonstrated encouraging results and the same protocol may be evaluated in a randomized control trial in future.

Conflicts of interest

None.

References

1. Cassini MA, Cerroni L, Ferlosio A, et al. The gingival stillman's cleft: histopathology and cellular characteristics. *Annali Di Stomatologia*, 2015; 6(3-4), 100-3.
2. Deepa D, Bhatia G, & Srivastava P. Gingival Stillmans Cleft- Revisited. *CODS Journal of Dentistry*. 2015; 7(2), 93-5.
3. Jati AS, Furquim LZ, & Consolaro A. Gingival recession: its causes and types, and the importance of orthodontic treatment. *Dental Press Journal of Orthodontics*. 2016; 21(3), 18-29.
4. Prasad DK, Shetty NS, & Solomon EGR. The Influence of Occlusal Trauma on Gingival Recession and Gingival Clefts. *The Journal of Indian Prosthodontic Society*. 2012; 13(1), 7-12.
5. Pilloni A, Dominici F, & Rossi R. Laterally moved, coronally advanced flap for the treatment of a single Stillman's cleft. A 5-year follow-up. *The European Journal of Esthetic Dentistry*. 2013; 8(3), 390-96.
6. Greggianin BF, Oliveira SC, Haas AN, et al. The incidence of gingival fissures associated with toothbrushing: crossover 28-day randomized trial. *Journal of Clinical Periodontology*. 2013; 40(4), 319-26.
7. Novaes AB, Ruben MP, Kon S, et al. The Development of the Periodontal Cleft: A Clinical and Histopathologic Study. *Journal of Periodontology*. 1975; 46(12), 701-9.
8. Deepa, D., Bhatia, G., & Srivastava, P. Gingival Stillmans Cleft- Revisited. *CODS Journal of Dentistry*. 2015; 7(2), 93-5.
9. Moskow BS. Repair of gingival clefts. *The Journal of the American Dental Association*. 1979; 98(6), 940-2.
10. Cairo F, Nieri M, Cincinelli S, et al. The interproximalclinicalattachmentleveltoclassify gingival recessions and predict root coverage outcomes: an explorative and reliability study. *Journal of Clinical Periodontology*. 2011; 38(7), 661-6.

11. Cawson RA, Odell EW. Gingivitis and Periodontitis. In: Cawson's essentials of oral pathology and oral medicine. 8th edition. Edinburgh: Churchill Livingstone; 2008.p.77-97.
12. Hallmon WW, Waldrop, TC, Houston GD, & Hawkins BF. Flossing Clefts: Clinical and Histologic Observations. Journal of Periodontology. 1986; 57(8), 501-4.
13. Miller PD. Root Coverage with the Free Gingival Graft. Journal of Periodontology. 1987; 58(10), 674-681. doi: 10.1902/jop.1987.58.10.674
14. Rocuzzo M, Bunino M, Needleman I, et al Periodontal plastic surgery for treatment of localized gingival recessions: a systematic review. Journal of Clinical Periodontology. 2002; 29(s3), 178-94.